

The Georgia ENTertainer

The Georgia Society of Otolaryngology / Head and Neck Surgery

GEORGIA SOCIETY OF OTOLARYNGOLOGY HEAD & NECK SURGERY

Board of Directors

PRESIDENT

Arthur J. Torsiglieri, MD

PRESIDENT-ELECT

Gregory Postma, MD

TREASURER

Amy Chen, MD, MPH

SECRETARY

Stephen Rashleigh, MD

IMMEDIATE PAST PRESIDENT

David J. Terris, MD

PRESIDENT MAESO/HNS

J. Andy Sipp, MD

AREA TRUSTEES:

Wendy L. Smith, MD - **North Georgia**
John DelGaudio, MD - **Atlanta**
William Moretz, III, MD - **Southeast GA**
Phillip Allen, MD - **Southwest GA**
William Grist, MD - **at large**

AAO/HNS BOARD OF GOVERNORS

Governor

Peter Abramson, MD

Legislative Rep

Jimmy J. Brown, MD, DDS, FACS

Public Relations Rep

Brian McKinnon, MD

Newsletter Editor

Stil Kountakis, MD, PhD

Tara M. Morrison, CAE

Executive Director

tara@theassociationcompany.com

Winter 2011

President's Message

by: Dr. Arthur J. Torsiglieri, MD



The New Year of 2012 began with continued drama and political rhetoric surrounding healthcare. From Obamacare to Accountable Care Organizations (ACOs), from Meaningful Use to Electronic Healthcare Records (EHR), having a strong state society can assist us navigate through the gauntlet of practicing present day medicine. The Georgia Society of Otolaryngology-Head and Neck Surgery (GSO-HNS) has been working hard on behalf of all otolaryngologists throughout the state of Georgia by safeguarding many aspects of our specialty. There is "strength in numbers" and the larger our society, the greater the impact we can have on legislative and reimbursement issues. I encourage every otolaryngologist to become an active member.

Before we begin 2012- let's review some of the milestones of the past year. After a very successful 2011 Summer Meeting at Amelia Island organized by Dr. David Terris, the GSO-HNS 2011 Fall Meeting was held in December at the Ritz-Carlton Lodge at Lake Oconee. This was the first time in many years that our Fall Meeting (usually done in conjunction with the Metro Atlanta Educational for Otolaryngology-Head and Neck Surgery) was held outside of Atlanta. This was a joint meeting with the Georgia Neurosurgical Society (GNS) and one of the highlights of the meeting was the inaugural GNS / GSO-HNS Golf Tournament. This was won by the GSO-HNS team (see photo later in the program). We hope to establish this as an annual event. The meeting was well attended with Dr. Marc Rosen from Jefferson Medical College of Thomas Jefferson University speaking on Endonasal Cranial Base Surgery. For those that attended, thank you for coming and I hope you enjoyed the accommodations that Lake Oconee had to offer. For those who missed it, you may have another opportunity because the GSO-HNS Board of Directors plans on having future events there.

The hallmark of our CME activity is our annual Summer Meeting. The 2012 Summer Meeting will offer a wonderful opportunity to connect with old fellow otolaryngology friends throughout the state, and to meet new ones. This meeting is a great source of pertinent information and offers a great mix of private practice and academic specialists in a casual setting. What better place to get together than in "America's Playground"- Orlando. Even my college age children are excited to be staying at the Loews Royal Pacific Resort and getting Express Access to Universal Studios and Isles of Adventures (and Harry Potter World)!

Many individuals work toward making GSO-HNS a model state society. As always, Tara Morrison and her association management company deserve kudos for keeping the GSO-HNS successful and making our meetings both educational and entertaining. I hope to see all of you and your families in Orlando in July!

Board of Governors 2012 Spring Meeting



The Spring BOG and Advocacy meeting is slated for Sunday May 6 – Tuesday May 8th. This will be a jam packed meeting that will start on Sunday at lunch time. The lunchtime discussion will focus on leadership involvement opportunities in the Academy.

The afternoon will encompass multiple committee meetings including the socio-economic grassroots, legislative, rules and regulations committees. Breakout sessions will feature workgroups discussing entrepreneurship focusing on potential business opportunities, Public Relations and Media Outreach, and Using the Web and Social Media Effectively.

Sunday evening there will be a wonderful reception at the George Washington Masonic Memorial sponsored by the ENT PAC.

Vicki LoPachin, MD, Medical Director of North Shore Hospital will be the featured speaker on Monday morning will deliver the keynote address: The Brave New World: Hospitals, Healthcare Systems, and the Modern Otolaryngologist. Also on Monday, Eric Mann, MD, from the FDA and Rodney Perkins, MD, a successful otolaryngologist-entrepreneur will lead a session called Developing and Patenting Your Ideas.

Monday afternoon will feature an otolaryngology advocacy summit led by members of the Academy government affairs team. Also, the Academy president-elect candidates will address the general assembly.

Tuesday May 8th will feature a briefing breakfast and then on to Capitol Hill to meet with our members of Congress.

This will be an informative and proactive meeting. Make plans to be there. No one can afford to sit on sidelines anymore.

Peter J. Abramson, MD
Governor, GSO-HNS
Chair, BOG Socioeconomic Grass Roots Committee

Georgia Health Sciences University

Update: *David Terris, MD*



Other notable recent honors include the bestowing of the American Rhinologic Society Educator Award to Vice-Chairman Stil Kountakis. Greg Postma (Director of the Center for Voice, Airway and Swallowing Disorders) took the reins as President of the American Broncho-Esophagological Association. He is also the President-Elect of the Georgia Society of Otolaryngology. Lana Jackson established Georgia's only sialoendoscopy program; a new robotic thyroidectomy technique was developed; and Arturo Solares has enjoyed a number of international opportunities to lecture on Skull Base surgery (including Nice, France; Santa Cruz, Chile; Monterrey, Mexico; and Guatemala).

As the department approaches the 10th anniversary of its transformation from a section of surgery to an independent Department, we find ourselves hitting on all cylinders and continuing our steady expansion. This year, we add 2 faculty members (and are recruiting for 2 more) while adding a 4th world-class fellowship.

Paul Weinberger returns to Augusta after completing an international laryngology fellowship at the world-renowned Royal College of ENT in London. Having completed his residency at GHSU, he brings a whole new dimension in airway reconstruction to the United States. He was jointly appointed to the Center for Biotechnology and Genomic Medicine.

Michael Groves arrived in August as a general otolaryngologist with a strong commitment to residency curricular development. Michael did his residency at Baylor after graduating from college at Harvard and medical school at the University of Michigan.

In a further sign of the clinical excellence offered in the Otolaryngology department at GHSU, a fourth fellowship is now being offered. In addition to Endocrine, Rhinology, and Laryngology, a Facial Plastic and Reconstructive Surgery fellowship position was developed under the directorship of Achih Chen, a faculty member for more than 8 years. The first fellow in FPRS will be Adam Becker, currently on the Faculty at Duke University.

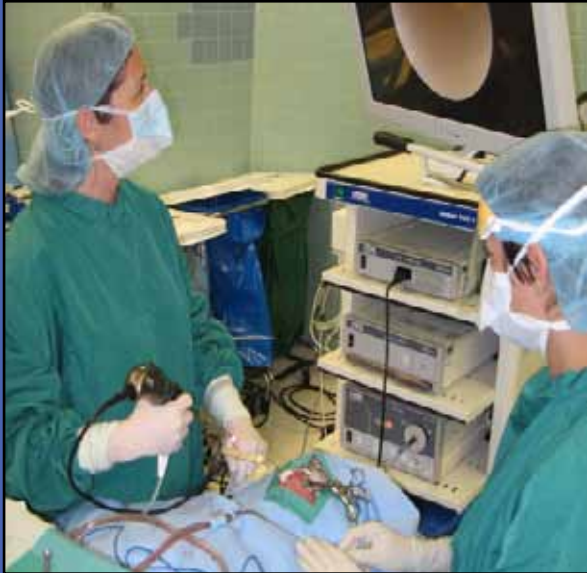

Paul Weinberger joins the faculty as a clinician-scientist

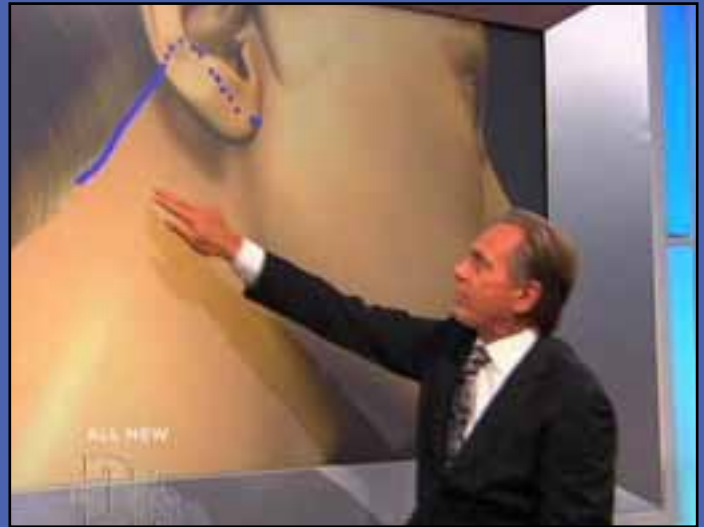

Michael Groves joins faculty as a general otolaryngologist

Georgia Health Sciences University Update: continued on page 4



Lana Jackon performs sialoendoscopy



Medical correspondent Andrew Ordon from The Doctor's Show indicates the location of the incision for the new robotic facelift thyroidectomy procedure described by Dave Terris."



Carestream

THE NEW AFFORDABLE POINT-OF-CARE CT

Introducing the CS 9300 system, a complete CT solution for sinus and temporal bone imaging that is easy to implement, accurate, and affordable. All from Carestream, a leader in medical imaging for over a century.

To discover the benefits of the CS 9300, visit www.carestream.com/ENT or call 888-477-4359.

© Carestream Health, Inc., 2011.



Case Report

Dr. Stil Kountakis, MD, PhD



Endoscopic management of allergic fungal rhinosinusitis with extensive skull base and orbital erosion.

Allergic Fungal Rhinosinusitis (AFRS) is believed to be a sinonasal mucosal inflammatory reaction by an immunocompetent host to fungi. The most common fungal particles involved are of the dematiaceous species. The most common fungal subtypes involved include *Curvularia*, *Bipolaris* and *Aspergillus*. AFRS affects approximately 5-10% of patients with chronic rhinosinusitis (CRS) and most cases are found in temperate regions of relatively high humidity. AFRS is most common in the relatively younger population and without sex predilection. Because of the high rates of recidivism, long-term patient follow-up is necessary to control the disease.

The diagnostic criteria for AFRS are as follows:

- Gel and Coombs type I (IgE-mediated) hypersensitivity to fungus
- Nasal polyposis
- Characteristic radiographic findings – Areas of hyper intensity and bone remodeling on sinus CT
- Eosinophilic mucin
- Positive fungal stains

Patients usually present with symptoms associated with CRS and nasal polyps, including nasal congestion and obstruction, rhinorrhea and olfactory dysfunction. If the disease is of long duration, patients may present with facial contour disfiguring and various degrees of orbital proptosis. For relatively unknown reasons, AFRS may present unilaterally or may involve a single sinus cavity.

Endoscopic examination in the office may reveal the presence of nasal polyps and thick proteinaceous and eosinophilic debris.

Radiologic evaluation with sinus CT imaging may reveal findings consistent with sinus opacification and nasal polyps with the presence of areas of hyper intensity and bone remodeling. Sinus cavities may be expanded by the accumulation of fungal debris resulting in orbital and skull base erosion. Magnetic resonance imaging (MRI) may show fungal debris with hypo intense signaling in T1 weighted images and with a central void in T2 weighted images.

Management of the disease requires surgical extirpation of the fungal debris followed by an aggressive medical regiment that may include use of oral steroid tapers, intranasal steroid delivery via nasal sprays, irrigation solution or a nebulizing device and possible desensitization to involved fungi. Postoperative debridement is most often needed to allow proper sinus mucosal recovery and careful long-term follow-up is necessary since these patients experience frequent recurrences.

Intranasal steroid irrigations have potent anti-inflammatory and immunomodulatory effects that can reverse early polypoid degeneration and inflammatory damage to sinus mucosa, they dilute and wash away inciting fungal antigens, and they lead to greater delivery of steroids to the sinus mucosa with less systemic absorption compared to oral steroids, leading to a much greater safety profile. Intranasal steroid irrigations may however cause low levels of systemic absorption, and should be used with caution in patients sensitive to chronic steroid medication.

Leukotriene inhibitors may also be beneficial in the prevention of AFRS recurrence. These drugs are active in blocking the formation and/or action of

Dr. Kountakis - Case Report continued on page 6

Dr. Kountakis - Case Report continued from page 5

leukotrienes in the inflammatory cascade of AFRS, however, supportive data is lacking.

Immunotherapy may also be used as an adjunct to AFRS therapy. Studies have suggested that AFRS recurrence diminished markedly in patients who are desensitized. Antifungals in the treatment of AFRS have been explored but supportive data is lacking.

When patients present with extensive orbital and skull base erosion, the goal of surgery is to remove all fungal debris while avoiding injury to important surrounding structures. In severe disease the bony barriers may be eroded, but injury to the dura and orbital periosteum during surgery should be avoided. The surgeon should be prepared to stage the procedure in cases where visualization is poor, if there is any degree of disorientation or if blood loss or anesthetic risk becomes too great. Dissection in the area of the frontal recess should be done with great care since polyp growth and accumulation of fungal debris may distort anatomic landmarks. Good visualization of both the skull base and medial orbital wall is paramount to dissection in this area. Conversely, the slow expansile nature of AFRS can enlarge natural sinus openings; therefore, even if fungal mucin resides in areas that are typically difficult to approach, the expansile tendency enlarges the natural outflow tracts, enabling greater access to the sinus cavity.

Interesting case report

A 19-year-old female presented with headaches and significant bilateral orbital proptosis causing diplopia. She also reported gradual changes in her mental function including bursts of uncontrolled aggressive and self-destructive behavior. The patient suffered from total nasal obstruction for several months and complete anosmia. Examination in the office revealed extensive polyps filling the nasal cavities, telecanthus and bilateral proptosis.

CT imaging showed extensive orbital and skull base erosion. Mucoceles and cavities filled with fungal debris eroded though posterior frontal walls and supraorbital cells causing significant frontal lobe compression and eye proptosis (Figure 1A,B). There was also erosion more posteriorly though the planum sphenoidale and

the posterior ethmoid roof with significant expansion of a cavity filled with fungal debris into the intracranial cavity (Figure 1C). There were hyper intense areas throughout the cavities classically indicating the presence of fungal debris, which was confirmed with sinus MRI. The MRI did not reveal obvious violation of the dura or orbital periosteum.

Endoscopic sinus surgery was performed and all fungal debris was carefully removed. Image guidance helped confirm whichever anatomic landmarks remained unaffected. The great difficulty was removing the debris from the cystic cavities compressing the frontal lobes and orbits through the posterior wall of the frontal sinuses and the supraorbital cells. As debris was gently removed, the decompressed dura with its brain contents was allowed to expand to take its more normal anatomic position anteriorly. Image guidance is based on preoperative data and becomes obsolete as intracranial and intraorbital contents migrate as they are decompressed. The surgeon should be patient and avoid overly aggressive surgical maneuvers to remove the

Dr. Kountakis - Case Report continued on page 7

Medtronic

Beyond Imagination

At Medtronic, we're changing what it means to live with chronic disease. We're creating therapies that help patients do things they never thought possible. Seeing our work improve lives is a powerful motivator. The more we do, the more we're driven to push the boundaries of medical technology.

Find out more at medtronic.com/Innovation

Innovating for life.

© 2011 Medtronic, Inc. All Rights Reserved.

Dr. Kountakis - Case Report continued from page 6

debris. Saline irrigations and valsalva maneuvers (performed on the patient by the anesthesiologist) assist in evacuating the cavities. Great attention is paid to the anterior ethmoidal arteries since their intranasal course may be completely displaced to an injury prone location. If completely unsure of the location of the artery while cutting through what it seems a bony wall of a cavity in the area of the frontoethmoid recess, it is wise to make the cut as medially as possible, closer to the septum, to prevent possible retraction of a severed artery into the orbit and orbital hematoma.

The procedure was completed without complications and the patient had an uncomplicated postoperative course that included endoscopic debridements in the office, oral steroid tapers, intranasal steroid spray and irrigation and leukotriene receptor blockade. Pathologic and microbiologic examinations of course confirmed the diagnosis of AFRS. The patient suffered from exacerbations of mucosal inflammation during the first year that were managed with prednisone tapers, but

the sinuses remained aerated and decompressed 2 years after surgery. She continued to improve and 4 years after surgery she now has stage 0 mucosal disease on nasal endoscopy and the sinus CT shows aerated and healthy sinus cavities (Figure 2). The patient is maintained on a nasal steroid spray and steroid nasal irrigations twice daily. She has not needed any oral steroid tapers for 2.5 years and all personality changes have dissipated. She will obviously require life long follow-up as disease recurrence can be imminent.

Conclusion

Patients with AFRS and extensive orbital and skull base erosion can be managed safely while maximizing postoperative mucosal inflammatory control. The key to successful uncomplicated outcomes is due diligence during endoscopic surgery in order to remove all fungal debris while avoiding injury to the dura and periorbita. Appropriate medical management and life-long follow-up are necessary to address the high rates of disease recidivism.

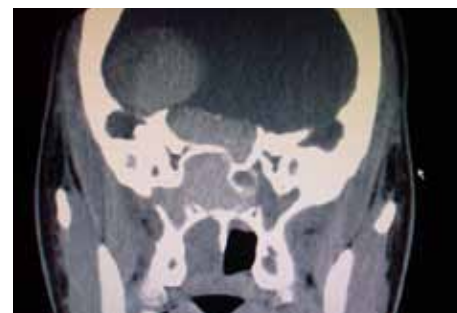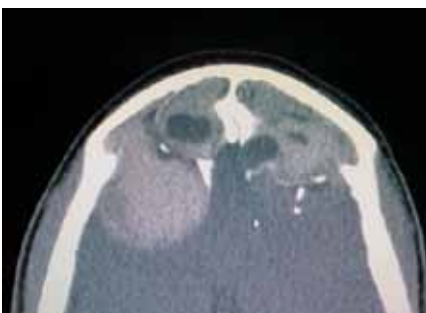

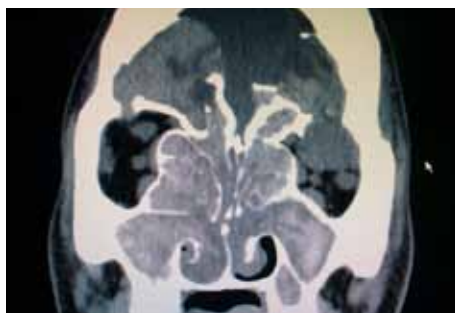
Figure 1a, 1b, 1c: Preoperative sinus CT imaging

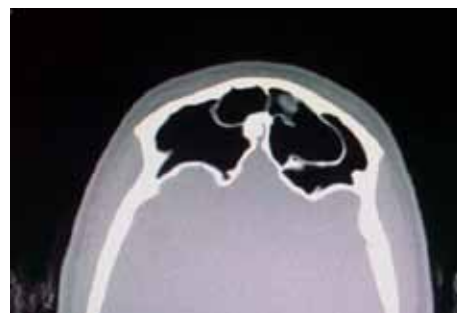
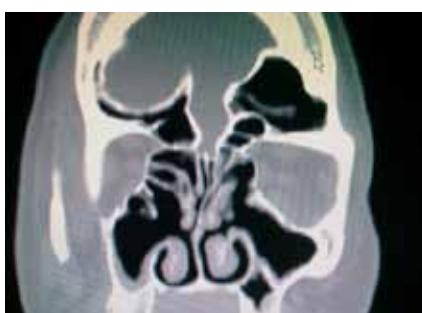
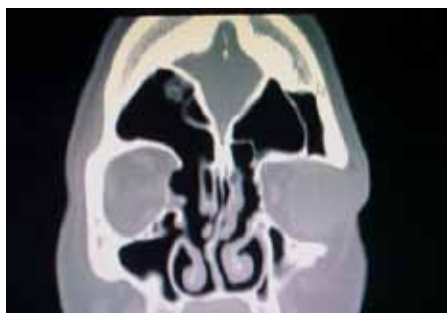
Figure 2a, 2b, 2c: Sinus CT 4 years after surgery

EMORY UPDATE:

by: Douglas Mattox, MD

Professor and William Chester Warren Jr., M.D. Chair
Department of Otolaryngology - Head & Neck Surgery



Greetings from Emory! All of the faculty, residents and staff at the Department of Otolaryngology - Head and Neck Surgery wish everyone a prosperous New Year. The Department has had new growth and development on several fronts which I would like to share with you.

New Faculty:

Zara Patel, MD, joined us as Assistant Professor with subspecialty training in Rhinology. Dr. Patel received her medical degree from Oregon Health and Science University and did her residency at Mount Sinai School of Medicine in New York. Her many awards and accomplishments include being a National Merit Finalist, Phi Beta Kappa, AOA, Leadership Grant from AAOA (twice) and the Mount Sinai Resident Teaching Award. Finally she did a fellowship in Rhinology at Stanford University Medical Center. Dr. Patel has a clinical interest in both inflammatory and neoplastic diseases of the sinuses.

Roy Rajan, MD, joined us as Assistant Professor with

subspecialty training in Pediatric Otolaryngology. Dr. Rajan received his medical education and at Temple University School of Medicine in Philadelphia and his residency at University of Tennessee Health Science Center. Dr. Rajan was involved with multiple class leadership activities in medical school and is an accomplished singer. He did a fellowship in Pediatric Otolaryngology at Johns Hopkins and joined our Pediatric group this past summer. He takes care of the full gamut of pediatric problems and has a focus on rhinologic problems.

Mark El-Deiry, MD, joined the Department as Assistant Professor with a subspecialty in Head & Neck Oncology and Microvascular Reconstruction. Dr. El-Deiry is a graduate of Emory University and received his MD at Rush Medical College in Chicago. After an internship at Swedish Hospital in Seattle followed by his residency at University of Iowa, he returned to the University of Washington for a fellowship in Head and Neck Oncology and Reconstructive Surgery. His first academic post was as Assistant Professor and Director of the Microvascular Head and Neck Fellowship at the University of South Florida in Tampa where he was involved in a number of clinical trials.



Departmental Growth:

The Department has been offered a grand opportunity to consolidate its outpatient activities and offices, now divided between the Clifton Road and Emory Midtown locations, entirely at Midtown. This project, now two years in planning, will come to fruition in June of this year. The new clinic will be located on the 9th floor of the Medical Office Tower of Emory Midtown, contiguous with the existing Emory Voice Center and Sinus Center. We are very excited about this transition which gives the

Department the opportunity for expansion and growth in clinic and office space, operating room availability and residency support. Emory University Hospital Midtown offers much improved patient access since it sits directly on the 85/75 downtown connector through the center of Atlanta.

Emory Update: continued on page 9

Emory Update: continued from page 8

Faculty Milestones:

Amy Chen, MD/PhD was nominated to the Editorial Board of Oral Oncology

Michael Johns, MD has had his Triological Thesis accepted and will be inducted as a Fellow at the Spring Combined Meeting.

Erick Lin, PhD will organize and chair an ARO Symposium: Using Massively-Parallel Next Generation Sequencing Techniques to Advance Studies and Clinical Care of Hearing Loss. Feb27, 2012. San Diego.



We defend.



THERE'S A GUIDING PHILOSOPHY TO MAG MUTUAL'S EFFORTS to defend your reputation. *Whatever it takes.* Claims committees staffed 100% by physicians. An exhaustive review and medical opinion for every claim filed. Outside help, when needed, to prepare a physician for deposition. Deep exploration of the best available expert witnesses. A detailed game plan weeks before trial. Testing the witness with focus groups. Mock trials. Continuous involvement of MAG Mutual's claims specialists.

Much of the above represents an "expense" to other carriers—an expense they often don't want to pay. So, they've often inclined to settle. *Not settling just to avoid cost but in the best interest of the physician, whose reputation, life and livelihood are at stake.*

MAG Mutual...a clear advantage.

***A.M. Best A (Excellent) rating
\$16.5 million dividend declared for 2011****

1-888-834-5950 • www.magmutual.com

*Dividend effective Jan 1, 2011. **2011 dividend payments are declared at the discretion of the MAG Mutual Insurance Company Board of Directors.

MAG MUTUAL*
MAG Mutual Insurance Company

INVESTMENT • FINANCIAL SERVICES
INSURANCE • PROPERTY MANAGEMENT

Want to Advertise in the ENT?

1/4 Page: \$1,000

1/2 Page: \$2,000

Full Page: \$4,000

For more information, please contact
Charlie Anderson at
othmar@mindspring.com
404.731.6591

GSO  **HNS**
The Georgia Society of
Otolaryngology/Head & Neck Surgery



Call for Award Nominations

We are now accepting nominations for the 2012 Lester Brown and Gerald Gussack

The Lester Brown Award:

*Must have a minimum of 20 years of practice in Georgia.

*Outstanding contribution to Otolaryngology/Head & Neck Surgery in Georgia.

PAST RECIPIENTS

1995	John S. Turner, MD	2004	Joel P. Smith Jr., MD
1996	Paul Keller, MD	2005	Michael Zoller, MD
1997	Edward S. Porubsky, MD	2006	William E. Silver, MD
1998	Jon Per-Lee, MD	2007	John Burson, MD
1999	Claude Pennington, MD	2008	William Moretz, Sr., MD
2000	Fred McConnell, MD	2009	Robin Schilling, MD
2001	George Harrison, MD	2010	William Grist, MD
2002	Gordon Brackett, MD	2011	Art Torsiglieri, MD
2003	NO AWARD GIVEN		

The Gerald S. Gussack Memorial Award:

*Must have a minimum of 10 years of practice in Georgia.

*Awarded for outstanding teaching of Otolaryngology/Head & Neck surgery. This can include teaching practicing physicians in any specialty, other otolaryngology-head & neck surgeons, medical students, residents, or allied health professions.

PAST RECIPIENTS

1996	Gerald S. Gussack, MD	2004	N. Wendell Todd, MD
1997	M. Edwin Davis, MD	2005	Patricia Hudgins, MD
1998	William Grist, MD	2006	Wallace Dyer, MD
1999	William E. Silver, MD	2007	John DeI Gaudio, MD
2000	Herbert Jones, MD	2008	Douglas Mattox, MD
2001	Hamilton Dixon, MD	2009	Pablo Stolovitzky, MD
2002	Frederick Kuhn, MD	2010	Peter Abramson, MD
2003	Frederick Klippert, MD	2011	Fred McConnell, MD

Log on to www.gsohns.org and click on the "Awards Section" or just
Click on the QR Code here.



Long Time GSO/HNS Member Elected as MAG First Vice President

At its recent annual meeting held in October at Callaway Gardens, the members of the Medical Association of Georgia [MAG] elected Dr William Silver as First Vice President for 2012. Dr Silver has served on its Board as Second VP for the past year. MAG has been the leading voice for the medical profession in GA since 1849. It is one of the leading organizations pursuing repeal of the Federal healthcare reform law that is felt to adversely affect healthcare providers and their patients. It also monitors state laws relating to tort reform, Third Party Payors, non-physician practitioners, and provision of quality medicine in GA.

In addition Dr Silver currently is a Board member of the Medical Association of Atlanta, a Fellowship Director of the American Academy of Facial Plastic and Reconstructive Surgery, a senior advisor to the American Board of Facial Plastic and Reconstructive Surgery, and Clinical Professor with the departments of Otolaryngology at Emory University and at Georgia Health Sciences University.

GEORGIA SOCIETY OF OTOLARYNGOLOGY

2012 ANNUAL MEETING

THURSDAY, JULY 19 - SUNDAY, JULY 22



REGISTER NOW! Scan this code from your smartphone to go directly to the GSO/HNS Meeting Details and Registration page.

Search QR Codes in your app store, download, and scan!

THE LOEWS ROYAL PACIFIC AT UNIVERSAL ORLANDO ORLANDO, FL

*Group room rates available at the hotel. FREE Universal Express access in both Universal Orlando theme parks when you stay at The Loews Hotel.

*For more information and Meeting Registration, please visit us online at www.gsohns.org

We proudly announce that
**First Professionals Insurance Company and
The Doctors Company have united.**

Together, we set a higher standard. We aggressively **defend** your name.
We **protect** good medicine. We **reward** doctors for their loyalty. We ensure
members benefit from our combined strength. We are not just any insurer.
We are the **nation's largest insurer** of physician and surgeon medical liability.

The Doctors Company and First Professionals Insurance Company (FPIC) have officially joined forces. With the addition of FPIC, we have grown in numbers, talent, and perspective—strengthening our ability to relentlessly defend, protect, and reward our 71,000 members nationwide. To learn more about how we can protect your livelihood and reputation with our medical professional liability program, call (800) 352-0320 or visit us at www.thedoctors.com.

*We relentlessly defend, protect, and
reward the practice of good medicine.*

